



Complicated Amoebic Liver Abscess: Which Is The Best Therapeutic Option?

Authors

Dr. Ketan Vagholkar¹, Dr. Urvashi Jain², Dr. Madhavan Iyengar³

¹MS, DNB, MRCS, FACS., Professor, Department of Surgery, D.Y.Patil University School of Medicine.
Navi Mumbai, MS, India

²MBBS, Senior Resident, Department of Surgery, D.Y.Patil University School of Medicine
Navi Mumbai, MS, India

³MS, Associate Professor, Department of Surgery, D.Y.Patil University School of Medicine
Navi Mumbai, MS, India

Corresponding Author

Dr. Ketan Vagholkar

Annapuran Niwas, 229 Ghantali Road. Thane 400602. MS. India.

Email: kvagholkar@yahoo.com

Abstract

Amoebic liver abscess is one of the commonest infective lesions of liver in the developing world. The complications of amoebic liver abscess need to be diagnosed at an early stage. Closed aspiration, percutaneous and surgical drainage are the three therapeutic options for complicated lesions. A proper choice of the procedure is pivotal in reducing the morbidity and preventing mortality in complicated cases of amoebic liver abscess. The natural history of surgical complications and the various therapeutic options are discussed in this paper.

Key words: amoebic liver abscess complications treatment surgery

Introduction

The incidence of complications in amoebic liver abscess varies from 20-35%. [1] Various factors play a role in the development of complications. These range from intrinsic host factors to the severity of the pathological process. [1, 2] In

majority of cases, rupture into the surrounding viscera or body spaces usually leads to increased morbidity and mortality. It is very important to understand the natural history of complications developing in amoebic liver abscess (ALA).

Surgical Complications of Amoebic Liver Abscess

Surgical complications are predominantly pleuro-pulmonary followed by pericardial and peritoneal. [3, 4] (Figure 1) Pleuro-pulmonary complications are more common. [5] This is due to the close proximity of the pleural spaces to the abscess cavity. Large abscess cavities occupying the posterosuperior aspect of the right lobe usually have increased pressure. This causes thinning of the overlying liver parenchyma and the adherent diaphragm eventually leading to rupture into the pleural spaces. Once ruptured into the pleural spaces, it can cause a wide range of complications. These include pleural effusion, empyema, pneumonitis and lung abscess. The condition if left untreated has extremely high morbidity as well as a high mortality.

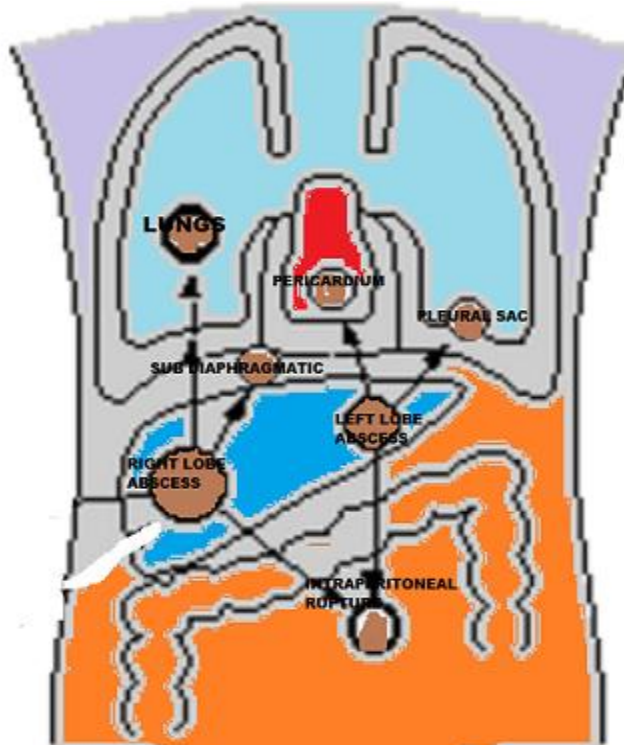


Figure 1

Surgical complications of amoebic liver abscess. (Rupture and spread to the pleura, lungs, pericardium and peritoneum.)

Abscesses involving the left lobe of liver have propensity to rupture into the pericardium. [3, 4] Though the condition is quite uncommon, yet in the event of it happening can lead to a fatal outcome. The patient usually develops cardiac signs suggestive of pericardial effusion, congestive cardiac failure or even both. Cardiac tamponade has also been reported. Patients with pericardial complications may present with abdominal symptoms. Prompt identification of this lethal complication is of utmost importance in preventing mortality.

Rupture into the peritoneal cavity is seen in those abscesses which point postero-inferiorly. Majority of abscesses are usually picked up at the pre-rupture stage wherein patients have abdominal signs and symptoms of a large liver space occupying lesion but devoid of any leakage of the abscess contents into the peritoneal cavity.[4,6] Rupture into the peritoneal cavity can present in a variety of ways such as generalised peritonitis or localised peritonitis. Extensive inflammatory reaction caused by the abscess cavity can lead to severe adhesions of the liver with the intestinal tract or even to the body wall. Cases of rupture into the intestinal tract have also been reported. The morbidity and mortality associated with intra-peritoneal rupture is extremely high if secondary infection supervenes.

Choice of Therapeutic Intervention

Drug therapy is the mainstay of treatment to begin with. [7] A variety of amoebicidal drugs are available. However, a proper choice of combination is necessary in order to achieve the

best results. One needs to take into consideration the differential penetration of tissue and luminal amoebicidal drugs. Emetine hydrochloride was the traditional drug for tissue amoebicidal effects. However, because of its cardio toxicity it is no longer used. The best combination is chloroquine phosphate with metronidazole. Periodic monitoring of symptoms, signs and radiological evaluation is essential to study the regression of the lesion. Periodic ultrasound is an extremely important tool to monitor the response to therapy. The exact anatomical location, site and the nature of the contents determine the response to treatment as well as the need for intervention. Majority of amoebic liver abscesses respond well to medical treatment. However, a select few may show poor response or may progress to the development of complications.

It is these complicated cases which pose a therapeutic dilemma. [7, 8, 9] A variety of therapeutic options can be exercised depending upon the severity of case.

Closed Aspiration

Closed aspiration is the commonest intervention for amoebic liver abscess. [10] The indications for closed aspiration include:

- 1) Persistence of symptoms despite adequate medical treatment
- 2) Abscesses of the left lobe with impending rupture into the pericardium
- 3) Suspicion that the abscess is secondarily infected
- 4) A previous aspirate of more than 250 cc.

Great precaution needs to be exercised prior to closed aspiration. (Figure 2) Coagulation profile within normal limits is absolutely necessary. The procedure is best done under strict aseptic precautions under USG guidance. It is preferable that the surgeon does the aspiration knowing very well about the anatomical aspects of the abscess cavity. Many a times, more than one closed aspiration may be required especially in large abscess cavities.

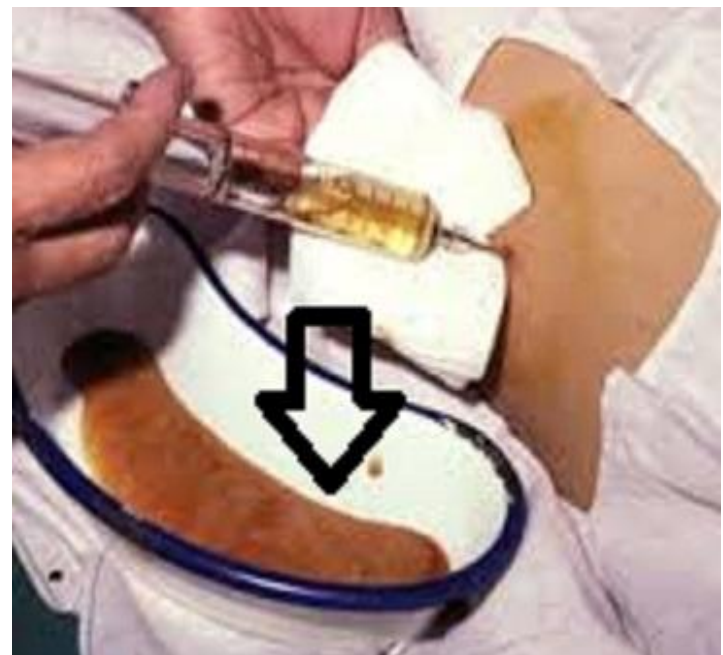


Figure 2

Technique of closed aspiration.
(Typical anchovy sauce like fluid aspirated from the cavity marked by the black arrow)

Percutaneous Drainage

Percutaneous catheter drainage may not be the best option for all abscess cavities. [9] It is particularly suitable for secondarily infected abscess cavities. There are very high chances of more super-added infections developing in these patients. The chance of amoebiasis cutis also needs to be taken into consideration. The routine

pigtail catheters which are used usually have a narrow lumen and are inadequate in draining the thick abscess contents. Therefore, this option is only suited for secondarily infected abscess with fluid contents.

Surgical Drainage

This is the procedure of choice for most of the ruptured abscess cavities. [11, 12] Rupture into the pleural space may necessitate thoracotomy with even decortication as tube thoracostomy may not suffice. For pericardial rupture or for rupture into pericardial cavity, closed aspiration under ultrasound guidance would be a safer option as compared to open surgical drainage. Open surgical drainage is best suited for intra-peritoneal rupture. A formal laparotomy to clear all the leaked contents is necessary. The abscess cavity needs to be completely drained. One needs to ensure the complete removal of the shaggy necrotic walls of the abscess cavity followed by irrigation with amoebicidal agent. Adequate drains need to be placed to ensure prevention of residual abscess cavity. A sub diaphragmatic, intra-cavitary and pelvic drain will ensure complete resolution of the local septic process. The chance of septicaemia in complicated amoebic liver abscess is higher as compared to unruptured abscesses. This may necessitate housing of this patient in the intensive care unit till clinical, haemodynamic and haematological parameters are brought within normal limits.

Conclusion

Closed drainage, percutaneous drainage and open surgical drainage are the three therapeutic options available for managing complicated amoebic liver abscesses. An optimum choice of procedure is best made based on the system involved by the complication and the general condition of the patient.

Acknowledgements

We would like to thank Mr. Parth K. Vagholkar for his help in typesetting the manuscripts and figures.

References

1. Seeto RK, Rockey DC. Amoebic liver abscess: Epidemiology, clinical features and outcome. *West J. Med.*1999; 170:104.
2. Thomson JE, Glasser AJ. Amebic abscess of the liver. *J Clin. Gastroenterol.*1986; 8: 550.
3. Meng XY, Wu JX. Perforated amebic liver abscess: clinical analysis of 110 cases. *South Med J.* 1994; 87(10): 985-90.
4. Mukhopadhyay M, Saha AK, Sarkar A, Mukherjee S. Amoebic liver abscess: presentation and complications. *Indian J Surg.* 2010; 72(1): 37-41.
5. Rasaretnam R, Paul ATS, Yoganath M. Pleural empyema due to ruptured amoebic liver abscess. *Br J. Surg.*1974;61:713.
6. Ramachandran S, Goonatillake HD. Amoebic liver abscess: Syndromes of "pre-rupture" and intraperitoneal rupture. *Br. J. Surg.*1974; 61:353.

7. Oschner A, Debaquey M. Diagnosis and treatment of amoebic abscess of the liver: A study based on 4484 collected and personal cases. *Am J Dig Dis.*1935; 2:47.
8. Akgun Y, Tacyildiz IH, Celik Y. Amoebic liver abscess: Changing trends over 20 years. *World J.Surg.* 1999; 23:102.
9. Thompson JE, JR, Forienza S, Verma R. Amoebic liver abscess: a therapeutic approach. *Rev Infect Dis.*1985; 7(2):171-9.
10. Bammigatti C, Ramasubramanian NS, Kadhiraavan T, Das AK. Percutaneous needle aspiration in uncomplicated amoebic liver abscess: a randomized trial. *Trop Doct.*2013; 43(1): 19-22.
11. Basile JA, Klein SR, Worthen NJ, Wilson SE, Hiatt JR. Amebic liver abscess. The surgeon's role in management. *Am J Surg.*1983; 146(1): 67-71.
12. Thompson JE Jr, Doty J, Wittenstein GJ, DenBesten L. Amebic abscess of the liver : surgical aspects. 1982; 136(2): 103-6.